

THE EFFECT OF RAMBUTAN PEEL EXTRACT (*NEPHELIUM LAPPACEUM L*) TO TOTAL LEUKOCYTES AND HISTOPATHOLOGICAL OF RAT LUNGS EXPOSED BY CIGARETTE SMOKE

Lisdiana¹, Nugrahaningsih W.H.², Priyantini Widyaningrum³

¹²³Department of Biology, Universitas Negeri Semarang
Email: lisdiana_512@yahoo.com

Abstract. Cigarette smoke is one of exogenous free radicals sources. When it is inhaled, its activity may damage the structure of lung function. The impacts of free radicals can be reduced through the provision of antioxidants. Rambutan fruit peel contains phenolic compound in the form of polyphenols that are antioxidants. The purpose of this study is to determine the effect of rambutan fruit peel extracts to the number of leukosit and lung structure on rats exposed by cigarette smoke. The research design used Post Test Control Group Design. A sample of 25 rats were divided into 5 groups, each group consisting of 5 rats. The positive control group (K +) were given a standard food and drinking water, the negative control group (K) by 3 cigarettes, the treatment groups (KP1, KP2, KP3) by 3 cigarettes and peel extract of rambutan each treatment group with a dose 15 mg/kg, 30 mg/kg and 45 mg/kg for 30 days. Total leukocyt measured by Auto Hematology Analyzer Mindray BC 2800vet. Total leukocytes and the damage of the lung were tested by one- way ANOVA. The number of leukocytes and damage to the lungs was analyzed by one-way ANOVA. and further tested with LSD. Next, the effective dose was tested by using linear regression. The result has shown that the average of total leukocytes in K+, K-, KP1, KP2, and KP3 was $6.28 \times 10^3/\mu\text{l}$, $11.98 \times 10^3/\mu\text{l}$, $9.88 \times 10^3/\mu\text{l}$, $8.48 \times 10^3/\mu\text{l}$, and $7.72 \times 10^3/\mu\text{l}$ respectively. Based on ANOVA, the rats have been exposed to cigarette smoke and given the extract of rambutan peel underwent decreasing total leukocytes and decreasing damage on alveolus more significant than those which has been exposed to cigarette smoke with no extract of rambutan peel. The effective dose of the extract of rambutan peel that was found to decrease total leukocytes and to protect the damage of the lung caused by cigarette smoke was 45 mg/kg body weight. Conclusion: the extract of rambutan peel was able to decrease the total leukocytes and protect the histopathological of rat lung that has been exposed to cigarette smoke.

Keyword: Rambutan peel extract; leukocyte; lung; cigarette smoke

INTRODUCTION

Cigarettes are processed product which is wholly or partially made of the leaf tobacco as raw material. Smoking activities have become lifestyle and habits in society. Each year tobacco-related deaths reached an estimated 4 million people, and by 2030 the number had risen to 8.3 million people. The high number of active smokers is directly proportional to the number of passive smokers who are exposed to the smoke of others (secondhand smoke). Cigarette smoke contains more than 4,000 harmful substances. These components are a source of harmful free radicals that cause oxidative stress. Oxidative stress by cigarette smoke will increase the number of leukocytes. The increase in leukocytes is a protective response to oxidative stress as a result of invading microbes, and heavy activity which is one source of free radicals. The peripheral white count is a source of information to diagnose the occurrence of oxidative stress. Many potential sources of the increase of free radicals in the body. One of them is the activity of leukocytes. Oxidative stress also lead to inactivation antiproteases. The effect of proteolytic enzyme collagenase elastase and will become dominant with the consequent increase in elastic tissue and collagen destruction of lung organ. Cigarette smoke resulted in a thickening of the alveolar wall, widening the alveolar lumen (Arkeman & David, 2006).

Rambutan (*Nephelium lappaceum* L.) have compounds that are useful as an antioxidant that has not been used in the pharmaceutical field. Rambutan fruit peel contains phenolic compounds such as geraniin and corilagin, both flavonoid and tannin from the group ellagic acid (Wulandari & Lestari, 2012). The content of rambutan peel extract also contains alkaloids, steroids, and terpenoids. The content of the chemical compounds most widely is phenolic compounds. These chemical compounds are antioxidants which can capture free radicals and reduce oxidative stress.

The high content of phenolic compounds is a good source of antioxidants as an exogenous source of antioxidants. Phenolic compounds suppressed the oxidative stress resulting from exposure to free radicals (Thitilertdecha et al., 2010). Based on the above, it can be underlined that free radicals caused by exposure to cigarette smoke will result in a thickening of the alveolar wall, widening the lumen of the alveoli. The use of antioxidants contained in the peel extract of rambutan can reduce oxidative stress and reduce the number of leukocytes. Rambutan fruit peel extracts provide protection and recovery of the histopathologic of the lung caused by exposure to cigarette smoke.

The objectives of this research are: to analyze the effect of rambutan peel extract towards

decreasing leukocytes amount; to analyze the effect of rambutan peel extract towards the rats histopathologic after being exposed to cigarette smoke; and to show the optimum dose of brambutan peel extract towards decreasing leukocytes amount and histopathologic recovery of the rats after being exposed to cigarette smoke

METHODS

Animal samples and Research Design

Rats were divided into five groups, namely K +, K-, KP1, KP2, and KP3. Rats were adapted to the environment for one week before being given treatment and were fed standard and drink ad libitum. On day one after adaptation, until day 30, for the group K only given food and drink only, negative control group only performed curing for 30 days, fumigation by three cigarettes at 08.00 am, 12.00 am, and 14.00 pm was performed every day. Fumigation in KP1, KP2, and KP3 at 08.00 am a single cigarette; rambutan peel extract treated with doses of 15, 30, and 45 mg/kg in at for 10 h. Then two hours later, it was performed two times of cigarettes fumigation sequentially to KP1, KP2, and KP3 at 12.00 and 14.00 pm for 30 days. The results were compared with the scoring guide. The scoring guide is used to show the degree of neutrophil infiltration, destruction of the alveolar septum, and a rat's pulmonary edema due to exposure to secondhand smoke among all groups.

Hematology analysis and Rat's Lung

Histopathological Observation

On day 31, all rats have blood drawn through the eye orbital sinus with a hematocrit of 2 ml. Blood samples were collected in tubes Eppendorf microcentrifuge tubes were washed with EDTA to prevent blood so that blood does not have coagulation. After the blood test with a total leukocyte count by using auto hematology analyzer. Then, surgery of rats (necropsy) was carried out in all groups after completion of the treatment for pulmonary. The samples were taken then were fixed with 10% formalin for histological preparations. Interpretation of the lung damage was completed through observation of histological preparations of lungs of rats using a microscope with a magnification of 400x. Then, the measurement scale of lung damage is in ordinal scale as mentioned by Larasati (2009) as shown in Table 1.

Table 1. Scores of rat lung degree of histological damage due to exposure to cigarette smoke

Nomina	Description lung damage	Scoring
Normal	No changes histologically□	0
Minor damage	lung alveolar damage> 0% - < 30%	1
Damage was damage	lung alveolar damage > 30% - < 60%	2
Heavily damaged	lung alveolar damage > 60%	3

The score from three parameters was then averaged; and then, the average yield was multiplied by 100% to get a percent value degrees of damage. The results of lung damage that have been obtained is classified based on the level of lung damage.

Data Analysis

Data analysis and interpretation of total leukocytes histological preparations was done with one-way ANOVA statistical test on a test level at 95%. ANOVA test results have a significant effect, followed by a test of Duncan Multiple Range Test (DMRT). Data analysis was performed using SPSS 17.0 for Windows. Qualitative data from the interpretation of lung damage was determined in the descriptive analysis by comparing normal lung histology with histopathological changes in lung structure each treatment.

RESULTS AND DISCUSSION

Total of leukocyte number

Exposure to cigarette smoke for 30 days trigger the total leukocyte counts rise response (Fig. 1) due to an increase in the number of free radicals. In normal circumstances, free radicals are formed in the body very slowly and gently. The high free radicals caused by exposure to cigarette smoke will cause some free radicals will exceed the capacity of endogenous antioxidant defenses and the immune response. Unbalance response endogenous antioxidants cause oxidative stress and stimulates the activity of leukocytes

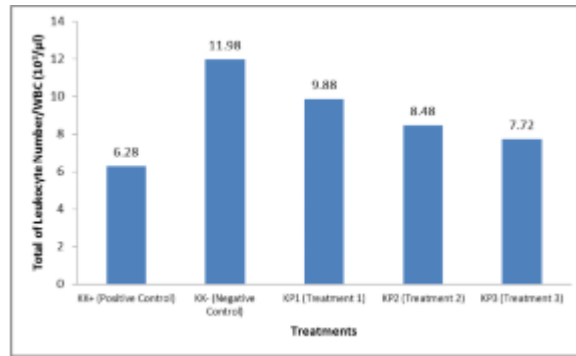


Figure 1. Results of total leukocyte

Statistical analysis showed that the positive control group, the mean number of total leukocytes was at 6,28x10³ /ml; whereas the exposure to cigarette smoke caused the increase in the total number of leukocytes into 11,98x10³/ml. Rambutan fruit peel extract highest dose showed a decrease in total leukocyte count with a value 7,72x10³ /ml.

Results of the linear regression of a total number of leukocytes data indicate a relationship between the dose of rambutan fruit peel extract and total leukocyte count levels with the linear regression model: $Y = 10.853 + (-0.072) X$. The linear regression ($R^2 = 0.78$) shows that a dose of rambutan fruit peel extract is 0 (zero), then the number of leukocytes totaling 10.853 and every dose increase by 1 (one) the levels of total leukocyte count increased by (-0.072). The coefficient is negative (-0.072) means there is a positive relationship between rambutan fruit peel extracts with the total number of leukocyte. A dose of 45 mg/kg body weight has a lower Y value (7.613) as compared to a dose of 15 mg/kg, and 30 mg/kg. Rambutan peel extract with a dose of 45 mg/kg/head/day dose was the most effective in lowering the total leukocyte number because it has a predictive value of total leukocyte number (Y) as the lowest.

The body has a non-specific defense system against foreign macromolecules that are considered to be antigen-smoking. Nicotine into the lungs will diffuse into the blood capillaries. Nicotine will circulate systemically into the body. The primary effect is caused by nicotine, which is mediated by receptors. Nicotine works as an agent against nAChRs (acetylcholine nicotinic receptors), which is found in the central and peripheral nervous system as well as the various cells in the body. Such as dendritic cells, T cells, B cells, keratinocytes, and macrophages.

When the immune system is decreased, leukocytes function as a defensive and reparative mechanisms. If these roles are continuously run, it will result in an increase in the number of leukocytes. Leukocyte which has increased the number due to smoking are lymphocytes, neutrophils, and monocytes. This result happens because of the local and systemic inflammatory response to the effects of smoke and foreign particles (Garini, 2013). The increase in the number of leukocytes due to a large number of leukocytes into the blood vessel walls (endothelium) by

way of diapedesis into the blood circulation of the temporary storage that resides in the body to fight free radicals.

Free radical molecules will bind the most vulnerable, namely in the form of lipids in cell membranes. Damage to the cell membrane causes disrupted cell membrane permeability. Therefore, the cells will become dehydrated. Damage to the cell permeability is causing the release of TNF- α induced by phagocytosis caused by lipid peroxidation, which is damage to the lipid membranes containing carbon-carbon double bond, resulting in cell damage in the alveolar membrane. Tumor necrosis factor-alpha (TNF-a) and increase levels of IL-8 as one of the proinflammatory cytokines serve to stimulate macrophages secrete chemokines that non-specific immune cells (macrophages) migrate into the tissue to get rid of pathogens.

Pulmonary Histopathology

Based on the data scoring in lung damage that has been tested using one-way ANOVA, it proves that the effect of rambutan fruit peel extracts on lung histopathology that had been exposed to cigarette smoke is significance 0.034 less than 0.05; whereas LSD at 5% level. LSD test results showed that the lung scoring result could be seen in the bar chart (Fig. 2).

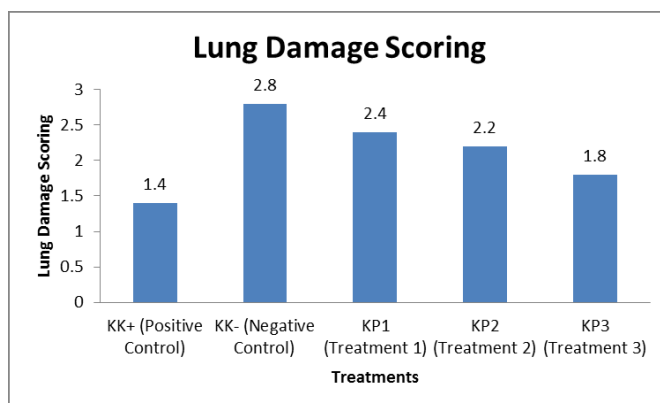


Figure 2. Results of scoring in lung damage

Results of linear regression test ($R^2= 0.78$) scoring lung damage indicate a relationship between the dose of rambutan fruit peel extract and the degree of lung damage with the linear regression model: $Y = 2.733 + (-0.02) X$. This equation means that when a dose of rambutan fruit peel extract is 0 (zero), then $Y = 2.733 + (-0.02) X$ is worth 2,733 and every dose increase by 1 (one), the scoring of lung damage increased by (-0.02). The coefficient is negative (-0.072) means that there is a positive relationship between the peel extract of rambutan with the scoring of lung damage. A dose of 45 mg/kg body weight has a lower Y value (1.833) as compared to a dose of 15 mg/kg, and 30 mg/kg. Therefore, the extract of rambutan peel with a dose of 45 mg/kg/head/day dose is most effective in reducing lung damage scoring, because it has the lowest

predictive value (Y). Exposure to cigarette smoke triggers oxidative stress, causing damage to the mucociliary clearance. Cilia are vibrating, and macrophage alveolar does not serve to eliminate foreign particles that enter the lungs, thereby increasing the risk of infection and inflammation in the lungs, according to research from the Kirana (2009) and Banerjee (2004), which states that, cigarette smoke leads to oxidative stress destructive pulmonary alveoli. Oxidants contained in cigarette smoke causes oxidative damage and significant at the microsomal protein and increase the occurrence of proteolysis resulting from an imbalance between proteases and antiproteases. Proteolysis and oxidative damage will cause damage to the alveolar wall and will ruin all parts of the lung. Figure 1-6 show the histopathology of lung damage in all groups of treatment. A letter shows the inflammatory cell infiltration, whereas B letter indicates the destruction of the alveolar septum, and C letter represents the pulmonary edema.

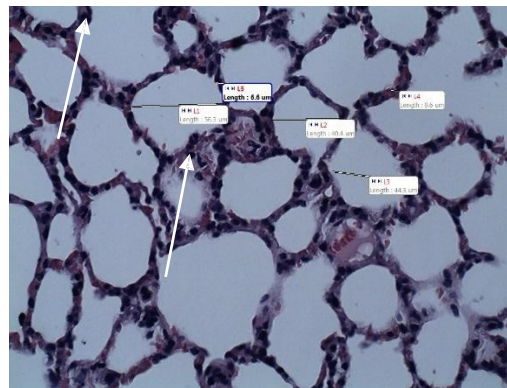


Figure 1. Histology Lung positive control group of rats with magnification of 400X

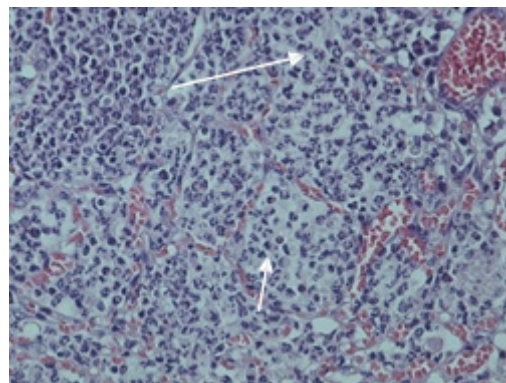


Figure 2. Histology negative control group of rats lung magnification of 400X

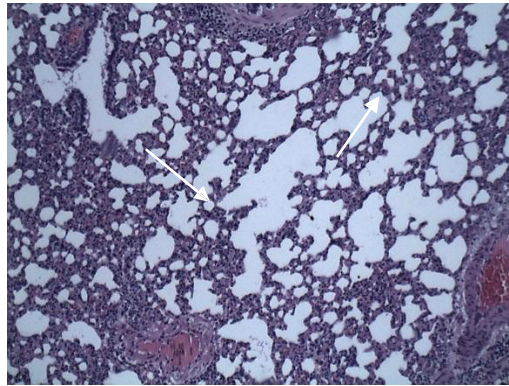


Figure 3. Histology negative control group of rats lung magnification of 100X

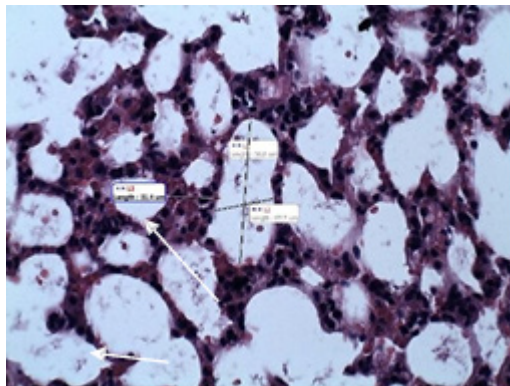


Figure 4. Histology lungs of rats treated group I magnification 400X

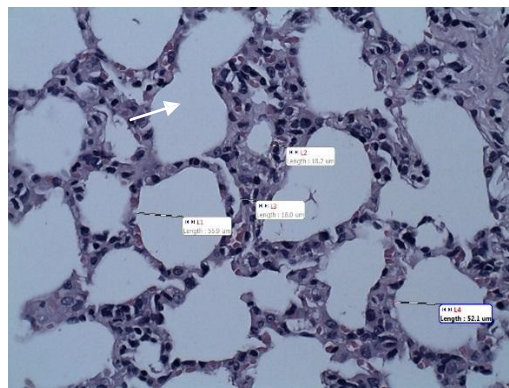


Figure 5. Histology lungs of rats treated group II a magnification of 400X

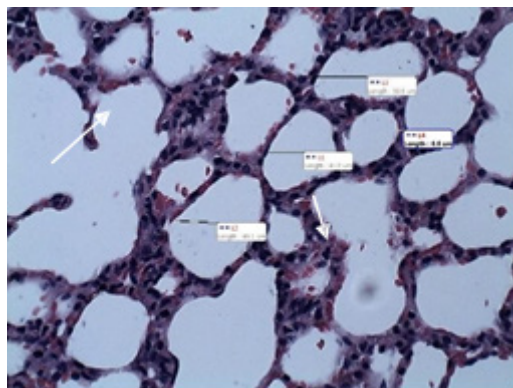


Figure 6. Histology lungs of rats treated group III a magnification of 400X

Inflammatory cell infiltration

Microscopic picture inflammatory cell infiltration in the form of sequestration of polymorphonuclear leukocytes, especially neutrophils in pulmonary microvascular. In the positive control group found mild infiltration. Untreated normal rats experienced mild stress, causing an imbalance in the body's physiological response. Stress experienced by rats also causes an imbalance in oxidants and antioxidants the body; high oxidant also triggers oxidative stress.

Severe damage to the alveoli present in the negative control group is seen in the observations found inflammatory cell infiltration with severe damage category. Infiltration of neutrophils fulfills alveolar septum, and into the alveolar space. Rats in the control group experienced an adverse chain reaction of free radicals, thus experiencing oxidative stress.

The process of inflammation is characterized by infiltration of inflammatory cells such as neutrophils which are in the alveolar septum, inflammation also causes activation of alveolar macrophages, and cause the release of chemotactic factors that bind to neutrophils, interleukin 8, and $TNF\alpha$. Infiltration of inflammatory cells cause swelling of the alveolar septum and if the condition is acute damage, inflammatory cells will meet the alveolar cavity (Idrus, 2014).

Destruction of alveolar septum

Microscopic picture destruction of alveolar septum was found in this study is their alveolar septal thinning, atrophy, and in some places, there is destruction and accompanied by enlargement of the ducts and alveolar sacs. In the positive control group experienced mild alveolar septum damage. Minor damage because alveolar septal thinning in some parts. This damage due to mild stress experienced by rats causes a chain reaction of free radicals, causing minor damage.

Oxidative stress in the negative control group causes the destruction of the alveolar septum, causing severe damage to the alveolar septum. Bulkheads between the alveolar suffered damage, so the size of the alveoli have a disproportionate size. Alveolar septal rupture occurs due to oxidative stress caused inactivation process antiproteases, so elastase and collagenase enzyme to

be increased. Due to an imbalance between antiproteases with elastase and collagenase enzyme are resulting in increased destruction of elastic tissue and collagen and lung. The impact of the destruction of elastic tissue and collagen causes alveolar septal tissue loses its elasticity.

Pulmonary edema

Microscopic picture of pulmonary edema on the observations preparations dosage form of the invention the membrane between the alveolar septum containing the liquid and hardly got any cell in the liquid and is characterized by increased alveolar septum lax.

The positive control group experienced pulmonary edema with mild and moderate damage. This image obtained due to external variables that can not be controlled such as the physiological state of rats, rats immunity, pathogenesis of a substance that causes damage lung structures other than cigarette smoke. And the regeneration of different cells in each rat. The negative control group experienced edema with severe damage. The chain reaction of free radicals causing capillary endothelial permeability increases. The constantly rising pressure filtration of fluid into the interstitial space of pulmonary alveoli. Plasma fluid filtration in the interstitial space causes interstitial pulmonary edema. The movement of plasma fluid in the alveoli causing alveolar pulmonary edema (Silbernagl, 2016).

Cigarette smoke contains various compounds that are harmful to health. The main toxins in cigarette smoke most, namely tar, nicotine, Pb particles, cyanide formaldehyde, and carbon monoxide. These substances are free radicals in the body. Nicotine into the body affects the brain or central nervous system, peripheral vessels constrict, and also has the characteristics of addictive and psychoactive effects. Carbon monoxide (CO) is a gas that has no odor. This element is produced by the incomplete combustion of carbon or carbon elements. Carbon monoxide gas is toxic. CO gas produced cigarette can reach 3-6%, while CO is inhaled by the smoker lowest number of 400 ppm (parts per million) has been able to increase the levels of carboxyhemoglobin in the blood of some 2-16% (Sitepoe, 1997). Tar is polynuclear hydrocarbon aromatic compounds that are carcinogenic. Tar in cigarettes contains 38 mg. Tar can damage lung cells because it can be sticky and stick to the airways and lungs, which causes cancer. Tar incoming to the human body has unpaired electrons. Because the electron is unpaired, then chemically will be paired with other electrons and reacted with the substance of the cell membranes, especially protein and unsaturated fats. Through the process of oxidation, cell membranes will undergo structural changes. The cell membrane becomes permeable to the substance of cigarette smoke so that these substances can enter through the cell membrane. The result will be a chain reaction of oxidative stress. Changes in the cell membrane is an inflammatory response due to the speed of destruction by oxidants of cigarette compared to the rate of repair and recovery of the cell membrane. The decline in lung damage in the experimental group one, two treatments, and the treatment of the

three, the due administration of rambutan fruit peel extract containing various substances that act as antioxidants in the body exogenous. High polyphenol content on rambutan fruit peel extract is an exogenous antioxidant that works together with flavonoids, alkaloids, and tannins.

Flavonoids can prevent oxidative stress in exposure to secondhand smoke. Flavonoids are found in the peel extract of rambutan allegedly could hinder the process of lipid peroxidation in the initiation stage, so that free radicals can not be developed into new free radicals. Flavonoids can provide rapid hydrogen atom to the lipid radicals (R^* , ROO^*) or change it to a more stable form. Such addition may block the oxidation reaction at the stage of initiation and propagation. These flavonoids are thought to potentially control and reduce lipid peroxidation chain-breaking antioxidants through a mechanism to capture radical ROO^- . Flavonoids can provide H^+ donor and bind to the radical ROO^- that this radical can be stabilized. This stability led to the cessation of lipid peroxidation chain reaction.

Award extract rambutan peel in rats exposed smoke may benefit to decrease total leukocyte count in rats that increased total leukocyte count due to exposure to cigarette smoke. Besides that it also provides benefits to improve alveolar lung tissue, so as to reduce the occurrence of emphysema is one of the symptoms of COPD (Marianti, 2009)

CONCLUSION

The extract of rambutan peel is influential for decreasing number of total leukocytes and can protect cell damage of alveolar lung which is exposed to cigarette smoke. The dose of rambutan peel extract at 45 mg/kg is mostly effective in decreasing the total of leukocyte and also reducing the degree of lung damage exposed to cigarette smoke.

REFERENCES

- Benowitz MDNL. 2008. "Neurobiology of nicotine addiction: implications for smoking cessation treatment". *The American Journal of Medicine* 121 (4A) : S3- S10.
- Fila WO, Johnson JT, Edem PN, Odey MO, Ekam V S , Ujong UP & Eteng OE. 2012 . "Comparative Anti-Nutrients Assessment of Pulp, Seed and Rind of Rambutan (*Nephelium Lappaceum*)". *Annals of Biological Research* 3(11): 5151 – 5156.
- Gordon, M. 1990. *The Mechanism of Antioxidant Action in Vitro*. in Hudson, B. J. F. (Ed.) *Food Antioxidants*. Elsevier Applied Science. New York .
- Ha liwe ll B & W hiteman M. 2 004. "M easuring reactive species and oxidative damage in vivo and in cell culture: how should you do it and wh at do the result mean?". *J Pharmacol*, 142: 2 3 1 - 255.
- Khonkarn R , Okonogi S, Ampasavate C & Anuchapreeda S. 2010. Investigation of fruit peel extracts as sources foor compounds with antioxidant and antiproliferative activities against human cell lines. *J Food and Chemical Toxicology* 48(8 -9): 2122-2129
- Lima VR, Morfim MP, Teixeira A, Crecszynski TB. 2004. "Relationship between the action of reactive oxygen and nitrogen species on bilayer membranes and antioxidants".

- Chemistry and physics of lipids* 132: 197-208
- Murray, R., Granner, K. & Rodwell, V.W. (2009). Biokimia Harper, Ed. 27. Jakarta: Penerbit Buku Kedokteran EGC.
- Nurdin BN, Yeni S & Emriadi. 2013. "Inhibisi Korosi Baja Oleh Ekstrak Kulit Buah Rambutan (*Nephelium lappaceum* Linn) dalam Medium Asam Sulfat". *J.Kimia Unand* 2(2): 133-143.
- Palanisamy P, Bakthavathsalam G, Rao YY & Farook J. 2009. Cigarette smoking-effect of metabolic health risk : a review. *Clinical Research & Review* 3:120 - 127
- Palanisamy U, Cheng HM, Masilamani T, Subramaniam T, Ling LT & Radhakrishnan AK. 2008. "Rind of the rambutan, *Nephelium lappaceum* a potential source of natural antioxidants". *J Food Chemistry* 109(1): 54-63
- Palanisamy U, Manaharan T, Teng LL, Radhakrishnan AK, Subramaniam T & Masilamani T. 2011. "Rambutan rind in the management of hyperglycemia". *J Food Research International* 44(7): 2278 -2282
- Ruchi GM, Majekodunmi OF, Ramla M, Gouri BV, Hussain A and Suad SB. 2007. "Antioxidant capacity of some edible and wound healing plants in Oman. *J.Food Chem* 101(2): 465-70
- Sandhiutami NMD, Rahayu L & Azilia NYN. 2015. *Antioxidant effect of ethanol extract from rambutan peel (Nephelium lappaceum) on malondialdehyde content and superoxide dismutase activity in mice*. Dalam: 1st APTFI CONGRESS International Symposium on Herbal Medicine. Makassar
- Shin HJ, Sohn HU, Han JH, Park CH. 2009. "Effect of cigarette filters on the chemical composition and in vitro biological activity of cigarette mainstream smoke". *J Food Chem Toxicol* 47 :192-197
- Thinkratok A. 2011. *Effects of the crude extract from the fruit rind of rambutan (Nephelium lappaceum L.) on obesity in male wistar rats*. (Thesis). Thailand: Suranaree University of Technology.
- Thitilertdecha, N., Teerawutgulrag, A., Kilburn, J.D. & Rakariyatham, N.(2010). Identification of Major Phenolic Compounds from *Nephelium lappaceum* L. And Their Antioxidant Activities. Article 15: 1453 - 1465
- Thitilertdecha N, Teerawutgulrag A & Rakariyatham N. 2008. "Antioxidant and anti bacterial activities of *Nephelium lappaceum* L. Extracts". *J Food Science and Technology* 41: 2029-2035
- Thitilertdecha N, Teerawutgulrag A, Kilburn JD, Rakariyatham N. 2010. "Identification of major phenolic compounds from *Nephelium lappaceum* L. and their antioxidant activities". *Molecules*, 15 (3) : 1453 - 1465 .
- Yanbaeva DG, Dentener MA, Creutzberg EC, Wesseling G & Wouters EF. 2007. "Systemic effect of smoking". *Chest* 131(5): 1557-1566
- Wulandari, N. & Lestari, S.R.2012. "The Potency of Rambutan (*Nephelium lappaceum*) Fruit Peel Ethanol Extract as an Antioxidant Natural Source Based on Viability Endothelial Cell". Makalah disajikan dalam Seminar International Life Science, Laboratorium Sentral Ilmu Hayati, Batu, 16-19 Juli.